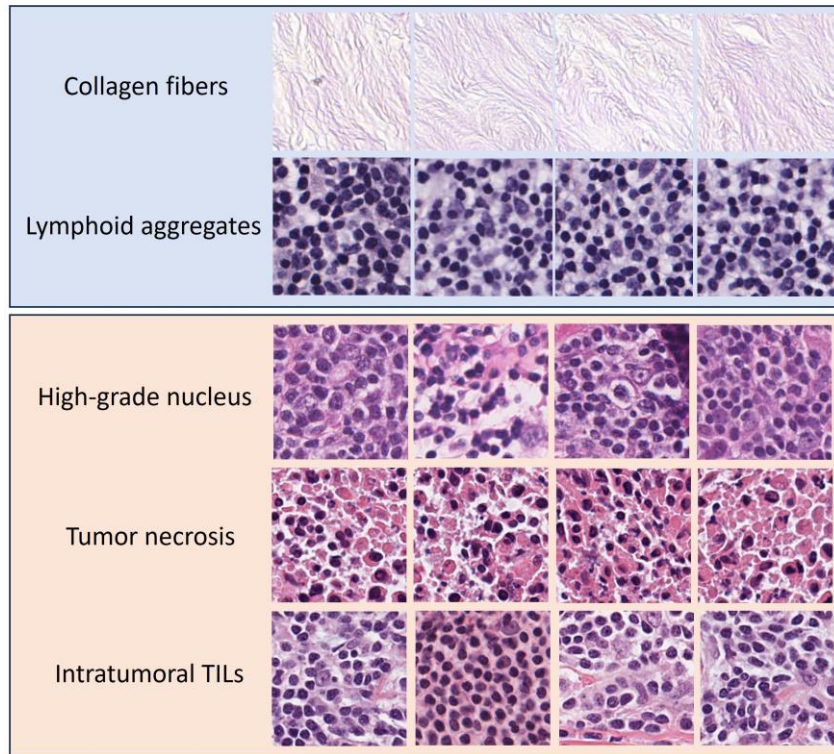
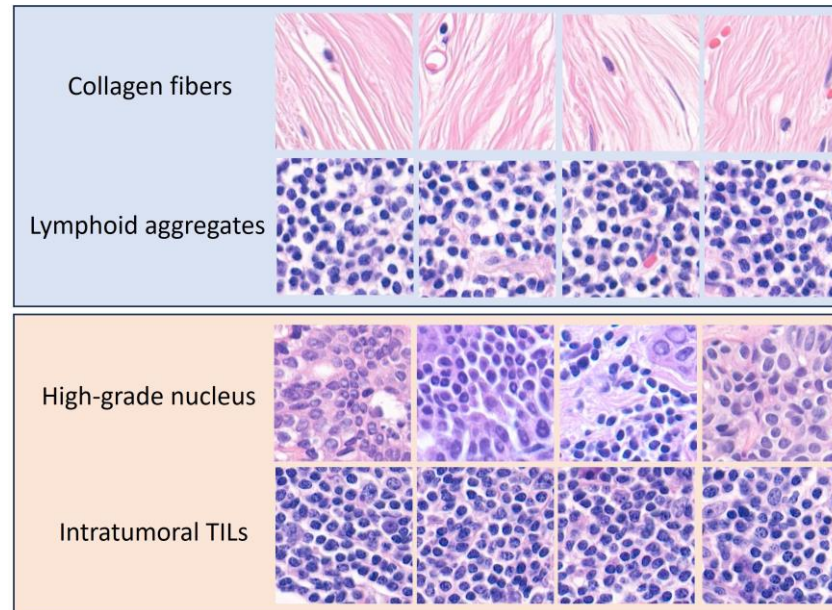


### A. Luminal A



### B. Luminal B



**S3 Fig.** Representative top attentive patches of the luminal A and B subtypes. Both subtypes showed a high frequency of collagen fibers and lymphoid aggregates. Luminal B did not exhibit patches of tumor necrosis (H&E stain,  $\times 200$ ).